

AAP-Commissioned Review

Temporary Anchorage Devices for Tooth Movement: A Review and Case Reports

Michael K. McGuire,*†‡ E. Todd Scheyer,*† and Ronald L. Gallerano*§

Background: Temporary anchorage devices (TADs) are immediately loaded miniscrews and osseointegrated palatal implants that are placed to control tooth movement during orthodontic treatment and removed when the treatment is completed. They are a relatively new addition to the dental armamentarium and can be used in some cases to replace traditional orthodontic extraoral appliances. Because placement requires a surgical procedure, orthodontists often refer patients to periodontists for this stage of the overall treatment plan.

Methods: The purpose of this article is to introduce TADs to the periodontal community by reviewing their purpose, various systems that are available, indications for use, site selection, and surgical technique. Case reports are included to illustrate this new treatment approach.

Results: Placement of osseointegrated implants for restorative purposes is an established procedure in most periodontal offices. Although placement of TADs is a modification of these familiar techniques, most of these devices serve a very different purpose, involving new loading protocols with no expectation of osseointegration in patients usually not receiving concomitant periodontal therapy.

Conclusions: Periodontists' knowledge of soft and hard tissue anatomy and their ability to manage soft tissue position them well to collaborate with orthodontists in this multidisciplinary treatment. However, as with every new modality, clinicians need to understand the specific uses and limitations of TADs and work closely with their referring orthodontists in identifying patients for whom miniscrew implants are a viable option. Periodontal practices are based primarily on referrals from dental colleagues, and the concept of periodontists working cooperatively with orthodontists is not new. Including TAD placement among the services periodontists offer provides another opportunity to further this relationship and to establish periodontists as appropriate resources for this segment of orthodontic treatment. *J Periodontol* 2006;77:1613-1624.

KEY WORDS

Dental implants; orthodontics; tooth movement.

Periodically, the Board of Trustees of the American Academy of Periodontology identifies the need for review of the literature on a specific topic and requests the Editor-in-Chief of the Journal of Periodontology to commission such a review. The selected author is solely responsible for the content, and the manuscript is peer reviewed, like all other Journal articles. The Academy's Board of Trustees does not review or approve the manuscript prior to publication, and the content of the review should not be construed as Academy policy.

Orthodontic anchorage is simply defined as the ability to limit the movement of some teeth while achieving the desired movement of other teeth. However, orthodontists have been searching for the most appropriate methods and appliances to achieve this goal since the 18th century.¹ The age-old problem in orthodontics is essentially the application of Newton's third law of motion: for every action, there is an equal and opposite reaction. When treatment planning, orthodontists must determine what those equal and opposite reactions will be. When attempting any desired tooth movements, orthodontists also must consider reciprocal effects on the final molar and canine relation, overjet, overbite, stability, the periodontium, and esthetics. Assuming ideal treatment goals, anchorage requirements need to be evaluated in three planes of space: anterior-posterior (AP), transverse, and vertical. Until recently, orthodontists relied on intra- and/or

* Private practice, Houston, TX.

† Department of Periodontics, University of Texas Dental Branch, Houston, TX.

‡ Department of Periodontics, University of Texas Health Science Center, San Antonio, TX.

§ Department of Orthodontics, University of Texas Dental Branch.

extraoral devices that usually required patient compliance to prevent undesired tooth movement to realize the desired occlusal results.

Although the idea of using a temporary device to establish skeletal anchorage was first explored in 1945,² the first case report did not appear until 1983.³ For a number of reasons, including the fact that implant dentistry was still in its infancy and surgical techniques were under development, it was not until just a few years ago that additional articles began to appear, all in the orthodontic literature and principally from clinicians in the Pacific Rim and European communities.⁴⁻¹⁷ Osseointegrated implants have been an important part of the periodontal armamentarium for more than 20 years. Periodontists have worked with orthodontists in placing them as an anchor to facilitate tooth movement prior to or during restorative treatment. However, temporary anchorage devices (TADs) are very different from their permanently placed counterparts, involving new loading protocols and surgical techniques.

In his excellent overview on TADs and their impact on orthodontics,¹⁸ Cope lists the following characteristics of the ideal anchorage device: simple to use, inexpensive, immediately loadable, immobile, does not require (patient) compliance, biocompatible, and provides clinically equivalent or superior results compared to traditional systems.

The primary purpose of this article is to introduce TADs to the periodontal community by explaining how they have altered orthodontic treatment planning, describing the various systems, reviewing techniques, and reporting on our shared, interdisciplinary clinical experiences. Our goal is to encourage periodontists to initiate dialog with their orthodontic colleagues and to explore the feasibility of including placement of TADs as part of their routine services.

ORTHODONTIC INDICATIONS

It is important for periodontists to have a basic understanding of the cases in which TADs may be useful in achieving desired orthodontic results. Table 1 outlines some of the current and potential uses of TADs in the three skeletal and dental planes of space that orthodontists must control for optimal results. The category “perimeter” refers to situations within the dental arches; “interactions” refers to considerations that can potentially modify the treatment plan. As the usage of TADs expands, more applications will undoubtedly unfold in each of these areas. Most of these indications are applicable to adults and children with either a full or partial dentition.

To the author’s (RLG) knowledge, the skeletal AP advantages cited in Table 1 have not been tested. However, the soft tissue and dental AP indications have been some of the primary uses of TADs to date. The

most important accomplishment has been the ability to eliminate headgear as an anchorage device in maximum anchorage cases, i.e., cases in which the anchorage teeth cannot move if an ideal result is the goal. This type of anchorage is often required in adults, who are extremely reluctant to comply with the time and esthetic requirements of headgear. The ability to maintain the maxillary incisor position in extraction cases by closing residual spaces from the posterior without the use of elastics is also revolutionary.

The vertical skeletal and dental category was first treated with TADs by Creekmore and Eklund³ in 1983 by intruding the maxillary incisors in a deep bite, adult female with excessive gingival display on smiling. TADs have also been used to facilitate restorative procedures in cases of one or more overerupted posterior teeth. Multiple well-documented case reports of molar intrusion, subsequent lower facial height decrease, and open-bite closure have been detailed in the literature.^{13,14,19-21} These reports demonstrated results previously unobtainable without orthognathic surgery. This has opened up new treatment possibilities for individuals who were unwilling or unable to have an orthognathic procedure performed due to the difficulty of obtaining third-party reimbursement.

TADs also permit a patient requiring extractions to be able to choose extraction of compromised teeth (e.g., restored, root canal, and malformed), rather than extracting virgin bicuspid to facilitate the final occlusal result. In summary, TADs give clinicians and patients attractive treatment alternatives. An organized list of orthodontic indications is provided in Table 1.

IMPLANT ANCHORAGE SYSTEMS

Osseointegrated Implants

The placement of osseointegrated implants as part of a restorative treatment plan is routine in most periodontal practices, and long-term success is an accepted outcome.²² Even though the technique is a less common one, most periodontists are also familiar with the use of osseointegrated implants to establish orthodontic anchorage, and they are retained as part of restorative treatment. As Smalley and Blanc reported,^{23,24} the procedures are technique sensitive and challenging. It is difficult to determine the exact location for implant placement in this situation because the final movement of the natural dentition cannot always be precisely predicted, and implants can be placed only in an edentulous or retromolar area; therefore, this option may not be practical for fully dentate adults or younger patients with deciduous or mixed dentition.²⁵

Palatal Implants

Unlike the other TADs discussed in this article, palatal implants or onplants are miniature, osseointegrated

Table 1.**Potential Uses of TADs for Orthodontic Purposes: Three Dimensions and Three Tissue Considerations (3D/3T)**

3D/3T	Anterior–Posterior	Vertical	Transverse
Skeletal	<ol style="list-style-type: none"> 1. Possibly as anchors to prevent unwanted dental movement during conventional orthopedic corrections such as those that occur with a Herbst appliance. 2. Possibly eliminate compensatory eruption of teeth occurring as a result of natural growth to yield a more anterior rather than vertical growth. 	<ol style="list-style-type: none"> 1. Intrusion of upper and/or lower facial height in cases of excess vertical growth through counterclockwise rotation of the mandible. 2. Possibly intrusion of entire upper and/or lower dental arch to eliminate excess alveolar display (“gummy smile”) in cases of vertical maxillary excess. 	<ol style="list-style-type: none"> 1. Possibly true orthopedic maxillary expansion, without the undesirable tipping of posterior teeth that occurs in traditional expansion.
Soft tissue	<ol style="list-style-type: none"> 1. Close spaces completely from the posterior to maintain the incisor position for optimal lip support. 2. Close spaces completely from the anterior to reduce excessive lip protrusion. 	<ol style="list-style-type: none"> 1. In select cases, eliminate lip incompetency through decreasing lower-face height. 	
Dental	<ol style="list-style-type: none"> 1. Close spaces completely from anterior or posterior congenitally missing teeth, possibly eliminating the need for bridge or implant. 2. Close spaces in cases of previously extracted or lost teeth, thus possibly eliminating a bridge or implant. 3. Retract maxillary and/or mandibular anterior segments completely without unwanted anterior molar movement, i.e., loss of posterior anchorage. 4. Uprighting tipped molars without extruding. 5. Maintain torque control of incisors during retraction by directing forces through the center of resistance. 6. En masse movement of arches mesially or distally to correct Class II or III molar and canine relations. 7. Asymmetric correction of Class II or III dental relation. 8. Correction of a canted occlusal plane. 	<ol style="list-style-type: none"> 1. Intrusion of overerupted upper and/or lower anterior teeth in cases of deep bite. 2. Intrusion of overerupted single or multiple posterior teeth. 3. Extrusion of impacted teeth without unwanted reciprocal effects on anchor teeth. 	<ol style="list-style-type: none"> 1. True unilateral movement of buccal segments to eliminate true unilateral cross-bites.
Other factors: I. Oral health	<ol style="list-style-type: none"> 1. May decrease orthodontic treatment time, thereby minimizing deleterious effect of orthodontic appliances on oral hygiene procedures. 		

Table 1. (continued)

Potential Uses of TADs for Orthodontic Purposes: Three Dimensions and Three Tissue Considerations (3D/3T)

3D/3T	Anterior–Posterior	Vertical	Transverse
2. Perimeter	<ol style="list-style-type: none">1. In cases requiring the extraction of permanent teeth, the orthodontist has the ability to choose a malformed, previously restored, or otherwise compromised tooth rather than a virgin tooth that might normally be needed in planning for anchorage requirements.2. In Class I cases having a non-extraction lower arch and congenitally missing one or two maxillary lateral incisors, there is the possibility of unilateral or bilateral space closure from the posterior; thus giving patient the option of substituting a canine for the lateral incisor instead of a bridge or implant.3. Ability to distalize molars through translation (i.e., bodily movement) rather than tipping.		
3. Interactions	<ol style="list-style-type: none">1. Eliminate the need for patient compliance in headgear or elastic wear; thus reducing treatment time.		

devices, but because they are removed after orthodontic treatment, they qualify as TADs.

A palatal implant system specifically designed for orthodontic treatment consists of a commercially pure titanium self-tapping implant (4 or 6 mm long and 3.3 mm in diameter) with a transmucosal collar (1.5, 2.5, or 4.5 mm long and 4.1 in diameter).¹¹ After placement and a healing period of ~3 months, anchorage is achieved by means of a transpalatal arch from the implant, attached to either the first molars or bicuspid. One obvious advantage to palatal implants, as opposed to traditional osseointegrated implants, is that they can be placed in fully dentate patients. Cousley²⁶ suggested that the orthodontist could use the time it takes for the palatal implant to integrate to align the anchor teeth so that the treatment period is not extended. Wehrbein et al.,^{15–17} who were involved in the development of this system, have published articles on their clinical experiences. Case report 1 provides an example of our team’s experience with a palatal implant.

Miniplates

This system is comprised of titanium plates in several shapes (L, I, T, and Y) and monocortical screws (2 mm in diameter; 5 mm long) placed in maxillary or

mandibular bone outside the dentition. After elevating a mucoperiosteal flap under local anesthesia, the malleable plates are shaped to the bone surface and secured in place using two or three screws, and the flap is sutured. Orthodontic forces are loaded after healing, and the plate and screws are removed after treatment. The principle advantages of miniplates compared to other TADs are that they do not interfere with tooth movement and the multiple screws provide more secure anchorage, which is especially beneficial in patients with extremely thin cortical bone, most often seen in those with excessive vertical facial height.¹³ Our team has not had experience with this system, but the articles by Sugawara and Nishimura,¹³ Sugawara et al.,¹² and Choi et al.⁴ provide information on miniplates.

Miniscrew Implants

Several other terms have been used to identify these TADs, including miniscrews,²⁷ screw-type implants, and microimplants.²⁸ We use Cope’s¹⁸ recommended phrase, “miniscrew implants,” which he defines as having a diameter of ≤2.5 mm.

As with osseointegrated implants used in restorative dentistry, there are a number of systems available.

|| Orthosystem, Straumann, Andover, MA.



Figure 1.
Two miniscrew implants with different configurations and sizes.

Periodontists should consult with their referring orthodontists to determine which to use because different loading appliances require different head configurations. All systems are made from either titanium or surgical-grade stainless steel and employ a conical or cylindrical screw design with asymmetric or symmetric thread pitch. Diameters range from 1.2 to 2.5 mm, and lengths range from 6 to 11 mm (Fig. 1). The principle variation is in the head shape, which is either a sphere with holes or a flat, slotted surface. Most of the systems on the market are self-tapping, although some of the more recently introduced ones are also self-drilling. Regardless of the design, the implant is usually placed after creating a pilot hole and can be immediately loaded with the orthodontic appliance. Case reports 2 and 3 illustrate surgical techniques.

TREATMENT PLANNING AND SITE SELECTION

After determining the facial and dental treatment objectives and tooth movement required to achieve these results, the orthodontist informs the periodontist of the selected site and the preferred placement angle. This information can be transferred between offices through written communication and/or by notations on study models. Effective communication is essential to achieve the desired results.

Radiographs

Radiographs are needed to evaluate the amount of bone available and to ensure that there is adequate space to insert the TAD without damaging the tooth root or other anatomic structures, such as nasal and sinus cavities and neurovascular bundles. Although pretreatment panoramic x-rays or cephalograms will be available from the referring orthodontist, clinicians may want to take periapical x-rays of the involved region, particularly if the TAD is to be inserted in the alveolar process. Some authors²⁹⁻³¹ recommend the use of computerized tomographs, but our team has not found them routinely necessary when a proper surgical technique is observed. Obviously, this is best determined on a case-by-case basis depending on the complexity of treatment.

Site Selection

Periodontists are highly qualified to place TADs because of their knowledge of soft and hard tissue anatomy. Once the orthodontist has identified the optimal site for the TAD, the periodontist can determine whether the local anatomy will permit placement. TADs are not traditional osseointegrated implants with which periodontists are most familiar, and anatomical parameters are different. Articles by Costa et al.³⁰ and Schnelle et al.³² provide good introductions to identifying appropriate sites for TAD placement.

Surgical Technique

Standard surgical protocols are applicable when placing TADs, and all patients must review and sign an informed consent. Although specific techniques vary with each system, palatal and miniscrew implants are generally placed under local anesthesia. Depending on the site and system used, TADs are placed using a flapless approach or a miniflap, the implant site is prepared under continuous sterile water or saline irrigation, and, after the implant is screwed into place, the site is closed, if necessary.

Case Report 1

This report involves a 40-year-old systemically healthy female who originally presented to the author (RLG) for a second opinion a week before she was to have orthodontic appliances placed. This patient reviewed and signed an informed consent and was treated by the authors between August 2001 and September 2004. The four first bicusps had already been extracted by the original orthodontist. In addition to the obvious severe Class II canine and retrognathic mandible, excessively proclined maxillary and mandibular incisors, and associated facial imbalance, advanced periodontal disease was noted. The patient was informed that additional bone loss would occur if orthodontics were to begin before periodontal health was achieved. Therefore, the extraction spaces were

stabilized with a fixed retainer, and the patient was referred for periodontal treatment.

The orthodontic treatment of choice was space closure with Class III mechanics (maximum retraction of the mandibular anterior segment and maximum mesial movement of the maxillary posterior segments) followed by a bilateral sagittal split ramus osteotomy, advancing the mandible to a Class I molar and canine relation and a concomitant genioplasty. The patient refused this treatment, so the possibility of a palatal implant was discussed and accepted, with genioplasty as an optional post-treatment. The patient's generalized chronic periodontitis was most severe in the molar regions and was treated with quadrant osseous surgery with regenerative procedures where possible. The preorthodontic tooth position is shown in Figure 2A. After resolution of active periodontitis, a radiographic guide was fabricated with a radio-opaque marker placed to represent the ideal implant position, and a lateral cephalogram was taken to access the palatal bone dimension in the desired location (Fig. 2B). Implant placement was performed under local anesthesia, and a 4-mm biopsy punch was used to remove the soft palatal tissue. The implant was allowed to integrate for 8 weeks before loading (Fig. 2C).

After completion of orthodontic tooth movement, the implant was removed under local anesthesia with a trephine, and the surrounding tissues healed uneventfully. The patient's postorthodontic tooth position is shown in Figures 2D and 2E, and the total lack of mesial movement of the maxillary molars with total space closure from the anterior is shown in the composite tracing (Fig. 2F).

Case Report 2

A 16-year-old female presented with a history of congenitally missing maxillary lateral incisors and previous orthodontic treatment that involved placing the maxillary canines in the lateral incisor position, leaving a unilateral space in the upper left quadrant (Fig. 3A). The original orthodontist's treatment plan called for closure of the maxillary lateral incisor space. As reported by her parents, the orthodontist experienced significant shifting of the maxillary midline to the left and decided to leave space for an implant in the canine position. A panoramic radiograph shows the apical root proximity in the upper left quadrant (Fig. 3B), and the periodontal clinical examination revealed a buccal ridge deficiency requiring both orthodontic retreatment for root alignment and alveolar ridge augmentation to allow for implant placement in the canine position. This treatment was offered, but the patient and her parents did not want an osseointegrated implant. Therefore, the decision was made to perform limited orthodontic treatment in the maxillary

arch to mesialize the posterior segment with a mini-screw distal to tooth #11 used as the primary anchorage unit. The patient and her parents reviewed and signed an informed consent. Figures 3C through 3E show the surgical miniscrew placement, and Figure 3F shows the 1-week loading of the miniscrew. The treatment was initiated in June 2005 and is currently in the completion phase of orthodontics. The current tooth position, after 12 months of anchorage, is shown in Figure 3G. Figure 3G also illustrates the flexibility to anchor an individual tooth with an auxiliary wire from the implant bonded to the tooth (#11).

Case Report 3

A 51-year-old systemically healthy female presented with a failing endosseous implant in place of tooth #28 (Fig. 4D). The implant had been in place for 10 years, and, although there were probing depths up to 9 mm, the implant was not mobile. The retained primary teeth #13, #20, and #29 were becoming increasingly mobile; the rest of the periodontium was stable.

The patient was interested in resolving the infection around her existing implant and wished to replace her retained primary teeth with new implant-supported restorations. She presented with a Class II malocclusion, and it was decided that it was not in her best interest to place the implants until this condition was corrected. The patient was offered orthodontic treatment using segmental mechanics with either four miniscrew implants (two buccal and two palatal on the right side) for anchorage or with a maxillary segmental osteotomy to intrude teeth #2 through #5. The patient selected the less invasive TAD option. It was also decided to eliminate the infection around the failing implant and temporarily retain it to be used as anchorage to move teeth #30 and #31. The replacement of the retained primary teeth and the failing implant with osseointegrated implants was scheduled after correction of the malocclusion. The patient reviewed and signed an informed consent and was treated by the authors beginning in August 2005 and is currently in the completion phase of orthodontics.

Periodontal therapy included the extraction of the retained primary teeth and debridement of the defect around the failing implant. At the same surgery, TADs were placed into the facial and palatal cortical plates at sites determined by the orthodontist, mesial to teeth #2 and #5 (Figs. 4A through 4C). These positions were chosen to provide absolute anchorage to intrude the right buccal segment and correct a very difficult orthodontic problem without orthognathic surgery. The combination of screws was chosen to control the anticipated tipping of the right buccal segment in the sagittal and transverse dimension. Before the TADs were placed, teeth #2 through #5 and #6 through #14 were segmentally aligned, and the

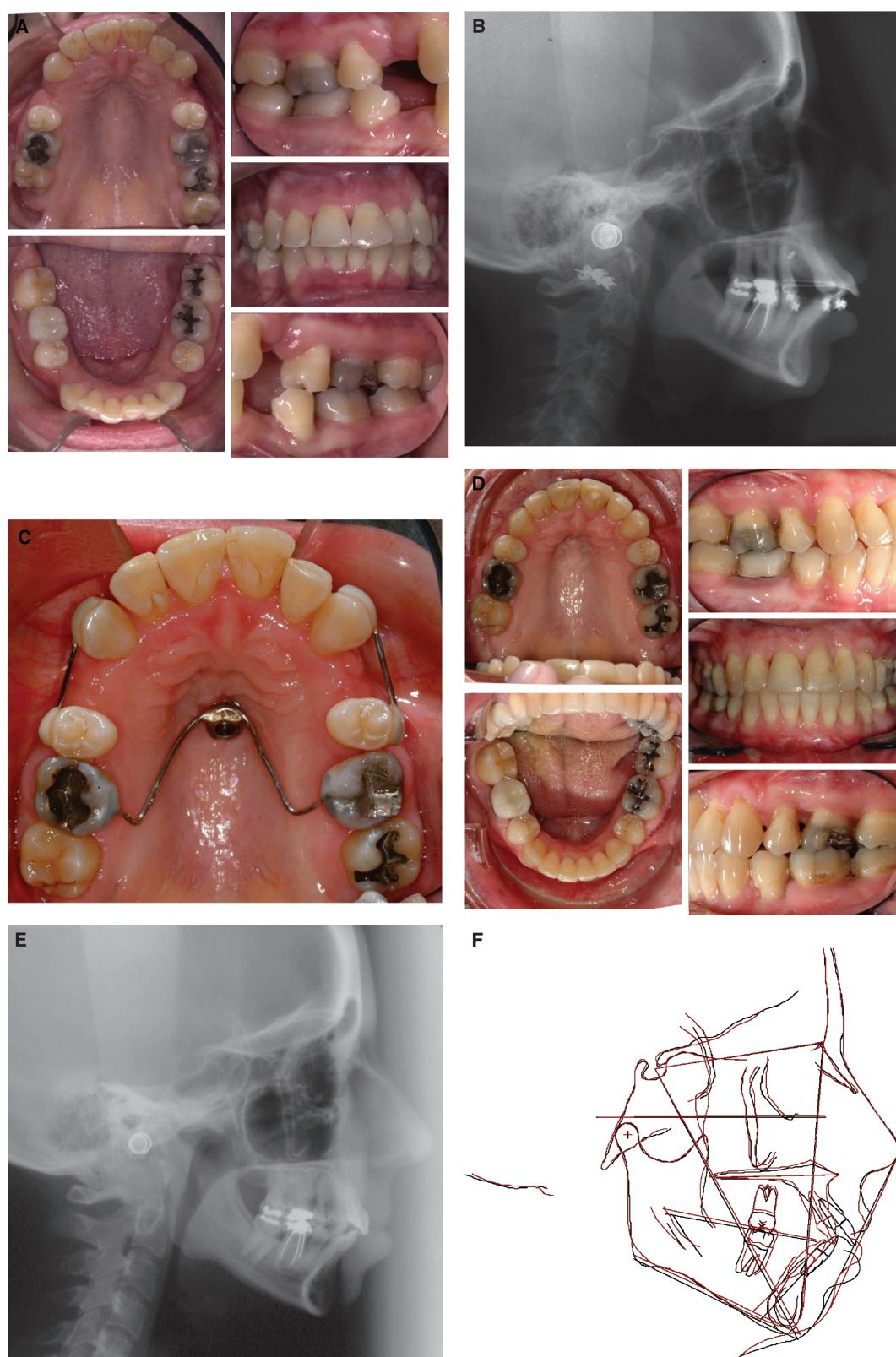


Figure 2.

A) Post-periodontal disease therapy and preorthodontic therapy patient presentation. **B)** Lateral cephalogram showing the radiographic marker specifying the optimal implant position and the correlating palatal bone dimension. **C)** The initial stages of implant loading after 8 weeks. **D)** Final tooth position after orthodontic treatment. **E)** Post-treatment cephalogram. **F)** Composite tracing showing no maxillary molar movement.

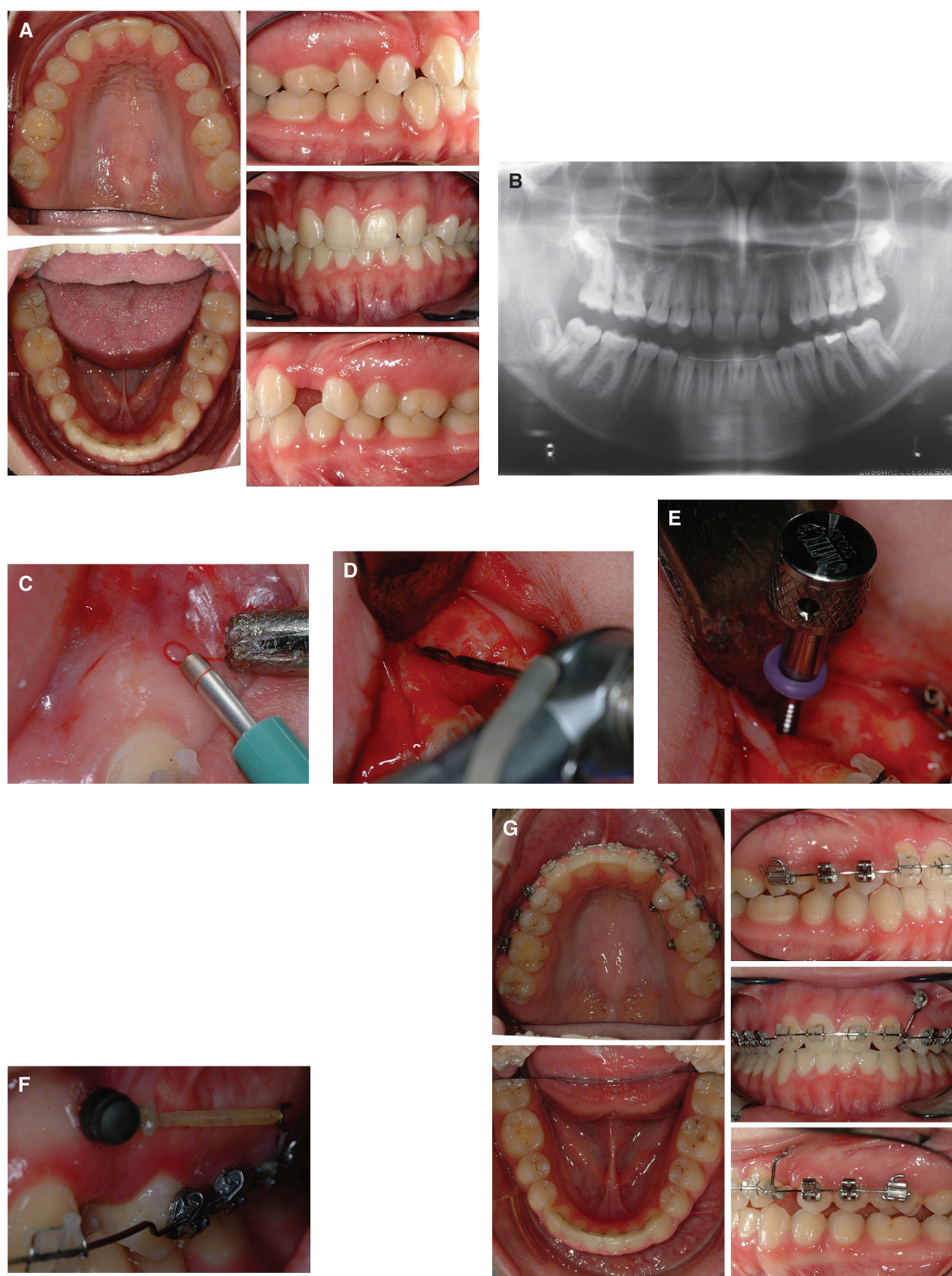


Figure 3.

A) Tooth position after initial orthodontic care. **B)** Panoramic radiograph showing root convergence at the potential implant site in the upper left quadrant. **C)** A 1.5-mm biopsy punch was used to excise the tissue. **D)** After the elevation of a full-thickness periosteal flap, the cortical plate was penetrated with a 1.1-mm twist drill. A flap was elevated to evaluate the canine root because the orthodontist recommended that the TAD be placed as close to the distal root surface as possible. **E)** The finger driver was used to insert the implant into the osteotomy. **F)** A 1-week postoperative view of the loaded TAD. **G)** The current tooth position, with favorable space closure after 12 months of anchorage.

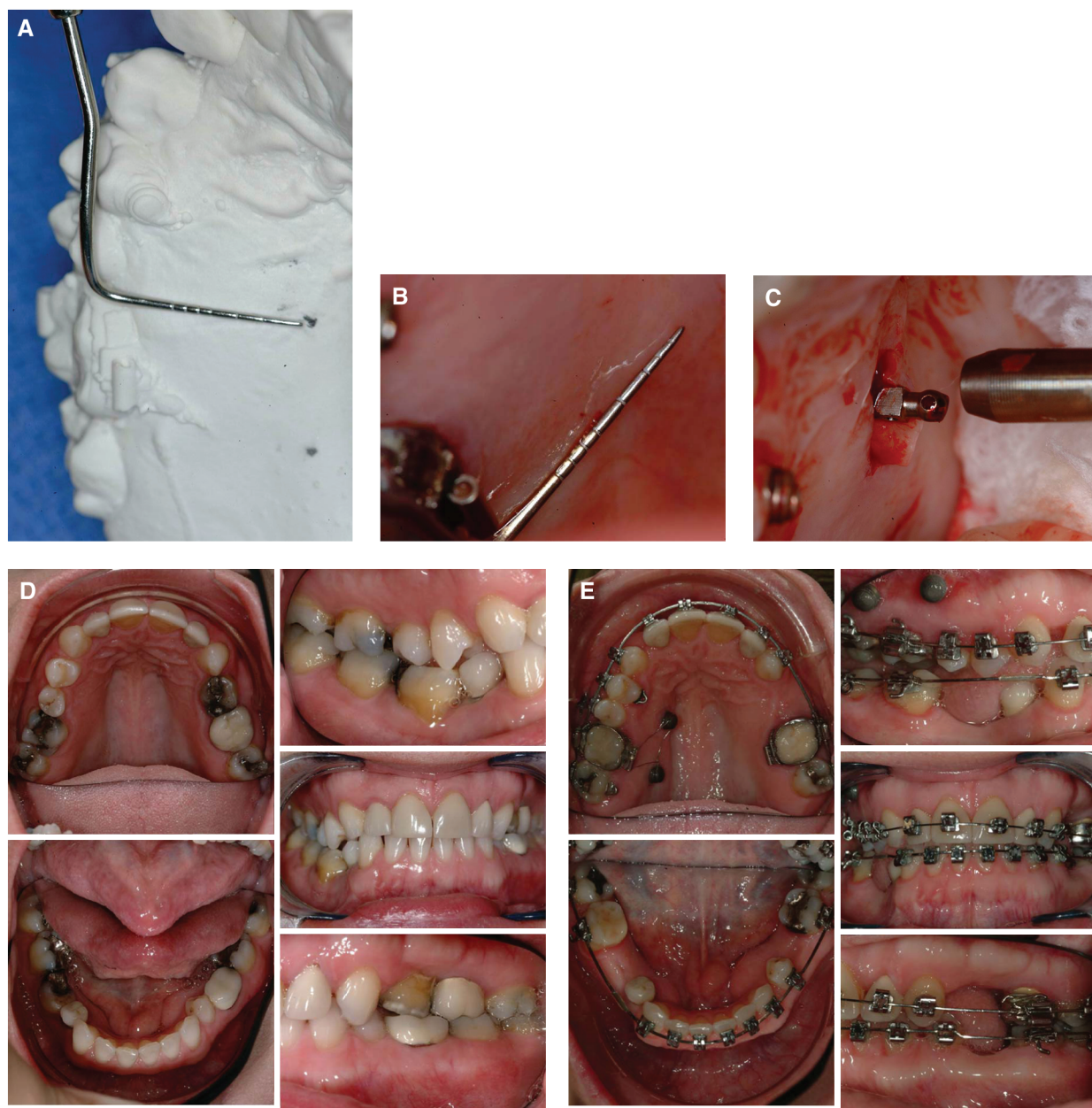

Figure 4.

A) A diagnostic model with TAD sites identified by the orthodontist. Note the desired position of the TAD interproximal and palatal to the maxillary molars. **B)** The selected sites on the model were identified in the patient's mouth using a periodontal probe. **C)** The TAD was placed with the driver using a self-drilling technique. **D)** Pretreatment photographs of tooth position. **E)** Current tooth positions after 8 months of intrusion.

mandibular arch was bonded. The progress to date is shown in Figure 4E.

Post-Surgical Treatment

Patients should be given standard surgical postoperative instructions emphasizing the importance of inflammation control and cautioned not to brush or touch the implant for a week. Ibuprofen or its equivalent is usually adequate for discomfort, and antibiotics are rarely necessary. A chlorhexidine rinse is usually

prescribed for 7 to 14 days, but no other post-surgical care is required. Patients with miniscrew implants should return to the orthodontic office as soon as possible for loading, preferably within 1 week. In theory, the vector of force to stabilize mini-implants is critical to counter tissue, tongue, and masticatory forces. Integration is not expected; therefore, mechanical stabilization is crucial. Patients receiving palatal implants may be scheduled in the periodontal office monthly until osseointegration is complete to monitor

mobility and possible inflammation. Unless periodontal therapy is part of the treatment plan, patients are then seen in the orthodontic office until the desired tooth movement is achieved and implants are ready for removal.

Removal

Because TADs are not osseointegrated, miniscrew implants are usually easily removed with the same driver used to place them, often only using topical anesthesia. Soft tissue closure is not necessary, and the wound heals within a few days. Palatal implants are removed using an osseous trephine under local anesthesia.

DISCUSSION

Although miniscrew implants are relatively new, our experiences and those of others^{4-17,25-28,33,34} clearly indicate they are becoming an accepted treatment option to more traditional methods of establishing orthodontic anchorage. For orthodontists and periodontists, the principle advantages of any of the systems are that they can be used regardless of the number or position of teeth, are easily placed and removed, reduce overall treatment time, allow for several tooth movements that were impossible before, and require minimal patient compliance. TADs can also provide treatment options that may minimize cost compared to other surgical interventions.

The most common TAD complications reported in the orthodontic literature appear to be screw fracture during either placement or removal,^{13,34,35} mobility,³³⁻³⁷ or inflammation of soft tissues at the insertion site.^{31,34-37} These situations can usually be resolved by inserting another implant (screw fracture; mobility) or applying chlorhexidine to the inflamed site. The possibility of damaging a tooth root, periodontal ligament, or nerve was mentioned by several authors,^{21,31,35,37} but none reported experiencing these complications. Our group has experienced implant fracture and postinsertion mobility. Fractured implants have been easily retrieved by grasping them with a needle holder and backing them out. Most TADs are self-drilling, and the clinician can easily feel if the implant touches a root. If this occurs, the implant can be redirected. Postinsertion mobility has been infrequent, but in most instances, the implant was easily removed and replaced with a stable fixture. One may encounter difficulty in removing a mobile implant and replacing it with another interradicular implant because adequate bone may not be available between the roots to allow for immediate replacement with proper stability. The mobile implant may have to be removed, the site allowed to heal, and a new implant placed months later.

The primary factors in successful placement of TADs are similar to those for osseointegrated im-

plants: proper site selection, the correct screw diameter and length, precise insertion, initial stability, and infection control. However, as mentioned above, the rationale for placing TADs and the anatomical parameters involved are very different considerations from those of traditional osseointegrated dental implants. For instance, one must consider the final three-dimensional position of the implant head, which should be in the proper location to optimize anchorage but not interfere with the desired total movement. Periodontists adding this treatment modality to their practices will want to review existing literature that discusses the optimal hard and soft tissue depths (see Costa et al.³⁰ and Schnelle et al.³² for a discussion from the orthodontist's perspective), which will affect the selection of the proper mini-implant.

Because TADs are a relatively new addition to treatment and most of the published literature consists of case reports and case series, there is limited evidence regarding success rates. In discussing microscrew sliding mechanics, Park et al.⁹ reported a 93% success rate at 18 months and 66% at 3 months. Results from another study by Park et al.¹⁰ using miniscrew implants reported 90% (27 of 30 placements in 13 patients over a mean of 12.3 ± 5.7 months) and 100% success when the lost screws were replaced without complication. Most of the devices evaluated had a 1.2-mm diameter and lengths varied from 6 to 15 mm. Miyawaki et al.¹¹ reported varying degrees of success with palatal and miniscrew implants: 96.4% (in seven patients using 2-mm-diameter and 5- or 7-mm-length palatal devices), 0% (three patients; 1.0-mm diameter; 7-mm length), 85% (10 patients; 2.3-mm diameter; 14-mm length), and 83.9% (31 patients; 1.5-mm diameter; 11-mm length). Cheng et al.³⁸ loaded 140 miniscrews, 48 for miniplates and 92 freestanding, in 44 patients and reported a cumulative success rate of 89% (125/140), with most failures occurring before or within 1 month of orthodontic loading and all caused by mobility. Bernhart et al.³⁹ placed 21 palatal implants in 21 patients and reported a loss of four after loading (mean: 4 months) due to peri-implant inflammation and a success rate of 84.8% at 22 months. Finally, Wehrbein et al.¹⁵ had no failures in the nine patients in whom they placed palatal implants over a loading period of 11 months \pm 3 weeks.

In general, these success rates are lower than those experienced with osseointegrated implants. It has been the authors' experience that the failure rate for these devices does exceed that of osseointegrated implants, and clinicians should be prepared for that possibility when incorporating a TAD as a treatment modality and when developing the treatment plan. Unlike osseointegrated implants, long-term stability is not a criterion for success because the miniscrews

are removed after orthodontic treatment. Furthermore, our experience indicates that a mobile mini-screw, unlike implants placed for restorative purpose, can be easily removed and another placed in an adjoining site with only minimal disruption of the treatment plan.

CONCLUSIONS

Clinicians interested in introducing TADs in their practice will want to first become familiar with the various systems and their unique advantages and disadvantages and then establish or increase communication with orthodontists in their area. Anecdotes indicate that American orthodontists are not likely to be interested in inserting or removing TADs and are seeking surgical partners to perform these procedures. With their knowledge of oral anatomy, extensive experience in implant placement, and history of interdisciplinary cooperation, periodontists are well positioned to place TADs.

As with all new modalities, TADs will require periodontists to have an understanding of their uses and limitations and to learn a new surgical technique. However, based on the experience of our team, the results are well worth the effort involved: expanding our scope of practice, adding new partners to our referral system, and ensuring that the orthodontic patient receives care from the two specialists best qualified to provide it. The ability to achieve absolute anchorage with TADs is rewriting the rules of orthodontic therapy, and periodontists must be prepared to partner with their orthodontists to provide our patients the best treatment outcome possible.

REFERENCES

- Weinberger BW. The history of orthodontia – Part 6. *Int J Orthod* 1916;2:103-117.
- Gainsforth BL, Higley LB. A study of orthodontic anchorage possibilities in basal bone. *Am J Orthod Oral Surg* 1945;31:406-416.
- Creekmore TD, Eklund MK. The possibility of skeletal anchorage. *J Clin Orthod* 1983;17:266-269.
- Choi B-H, Zhu S-J, Kim Y-H. A clinical evaluation of titanium miniplates as anchors for orthodontic treatment. *Am J Orthod Dentofacial Orthop* 2005;128:382-384.
- Hong R-K, Heo J-M, Ha Y-K. Lever-arm and mini-implant system for anterior torque control during retraction in lingual orthodontic treatment. *Angle Orthod* 2004;75:129-141.
- Kawakami M, Miyakawa S, Noguchi H, Kirita T. Screw type implants used as anchorage for lingual orthodontic mechanics: A case of bimaxillary protrusion with second premolar extraction. *Angle Orthod* 2004;74:715-719.
- Park H-S, Bae S-M, Kyung H-M, Sung J-H. Case report: Micro-implant anchorage for treatment of skeletal Class I bialveolar protrusion. *J Clin Orthod* 2001;35:417-422.
- Park H-S, Kwon T-G. Sliding mechanics with micro-screw implant anchorage. *Angle Orthod* 2004;74:703-710.
- Park H-S, Kwon O-H, Sung J-H. Microscrew implant anchorage sliding mechanics. *World J Orthod* 2005;6:265-274.
- Park H-S, Lee S-K, Kwon O-H. Group distal movement of teeth using microscrew implant anchorage. *Angle Orthod* 2005;75:602-609.
- Miyawaki S, Koyama I, Inoue M, Mishima K, Sugahara T, Takano-Yamamoto T. Factors associated with the stability of titanium screws placed in the posterior region for orthodontic anchorage. *Am J Orthod Dentofacial Orthop* 2003;124:373-378.
- Sugawara J, Daimaruya T, Umemori M, et al. Distal movement of mandibular molars in adult patients with the skeletal anchorage system. *Am J Orthod Dentofacial Orthop* 2004;125:130-138.
- Sugawara J, Nishimura M. Minibone implants: The skeletal anchorage system. *Semin Orthod* 2005;11:47-56.
- Umemori M, Sugawara J, Mitani H, Nagasaka H, Kawamura H. Skeletal anchorage for open bite correction. *Am J Orthod Dentofacial Orthop* 1999;115:166-174.
- Wehrbein H, Feifel H, Diedrich P. Palatal implant anchorage reinforcement of posterior teeth: A prospective study. *Am J Orthod Dentofacial Orthop* 1999;116:678-686.
- Wehrbein H, Merz BR, Diedrich P, Glatzmaier J. The use of palatal implants for orthodontic anchorage. Design and clinical application of the orthosystem. *Clin Oral Implants Res* 1996;7:410-416.
- Wehrbein H, Glatzmaier J, Mundwiler U, Diedrich P. The Orthosystem – A new implant system for orthodontic anchorage in the palate. *J Orofac Orthop* 1996;57:142-153.
- Cope JB. Temporary anchorage devices in orthodontics: A paradigm shift. *Semin Orthod* 2005;11:3-9.
- Chang Y-J, Lee H-S, Chun Y-S. Microscrew anchorage for molar intrusion. *J Clin Orthod* 2004;38:325-330.
- Freudenthaler JW, Hass R, Bantleon H-P. Biocortical titanium screws for critical orthodontic anchorage in the mandible: A preliminary report on clinical applications. *Clin Oral Implants Res* 2001;12:358-363.
- Herman R, Cope J. Miniscrew implants: IMTEC mini ortho implants. *Semin Orthod* 2005;11:32-39.
- Adell R, Lekholm U, Rockler B, Brånemark PI. A 15-year study of osseointegrated implants in the treatment of the edentulous jaw. *Int J Oral Surg* 1981;10:387-416.
- Smalley WM. Implants for tooth movement: Determining implant location and orientation. *J Esthet Dent* 1995;7:62-72.
- Smalley WM, Blanc A. Implants for tooth movement: A fabrication and placement technique for provisional restorations. *J Esthet Dent* 1995;7:150-154.
- Kokich VG. Managing complex orthodontic problems: The use of implants for anchorage. *Semin Orthod* 1996;2:153-160.
- Cousley R. Critical aspects in the use of orthodontic palatal implants. *Am J Orthod Dentofacial Orthop* 2005;127:723-729.
- Dalstra M, Cattaneo PM, Melsen B. Load transfer of miniscrews for orthodontic anchorage. *Orthodontics* 2004;1:53-62.

28. Chung K, Kim S-H, Kook Y. C-Orthodontic microimplant for distalization of mandibular dentition in Class III correction. *Angle Orthod* 2005;75:119-128.
29. Rungcharassaeng K, Kan JYK, Caruso JM. Implants as absolute anchorage. *J Calif Dent Assoc* 2005;33:881-888.
30. Costa A, Pasta G, Bergamaschi G. Intraoral hard and soft tissue depths for temporary anchorage devices. *Semin Orthod* 2005;11:10-15.
31. Carano A, Velo S, Incorvati C, Poggio P. Clinical applications of the mini-screw anchorage system (M.A.S.) in the maxillary alveolar bone. *Prog Orthod* 2004;5:212-230.
32. Schnelle MA, Beck FM, Jaynes RM, Huja SS. A radiographic evaluation of the availability of bone for placement of miniscrews. *Angle Orthod* 2004;74:832-837.
33. Crismani AG, Bernhart T, Bantleon H-P, Cope JB. Palatal implants: The Straumann Orthosystem. *Semin Orthod* 2005;11:15-23.
34. Melsen B. Mini-implants: Where are we? *J Clin Orthod* 2005;39:539-547.
35. Melsen B, Verna C. Miniscrew implants: The Aarhus anchorage system. *Semin Orthod* 2005;11:24-41.
36. Costa A, Raffaini M, Melsen B. Miniscrews as orthodontic anchorage: A preliminary report. *Int J Adult Orthod Orthognath Surg* 1998;13:201-209.
37. Maino BG, Mura P, Bednar J. Miniscrew implants: The Spider screw anchorage system. *Semin Orthod* 2005;11:40-46.
38. Cheng S-J, Tseng I-Y, Lee J-J, Kok S-H. A prospective study of the risk factors associated with failure of mini-implants used for orthodontic anchorage. *Int J Oral Maxillofac Implants* 2004;19:100-106.
39. Bernhart T, Freudenthaler J, Dortbudak O, Bantleon H-P, Watzek G. Short epithetic implants for orthodontic anchorage in the paramedian region of the palate. A clinical study. *Clin Oral Implants Res* 2001;12:624-631.

Correspondence: Dr. Michael K. McGuire, Suite 102, 3400 S. Gessner Rd., Houston, TX 77063. Fax: 713/952-0614; e-mail: mkmperio@swbell.net.

Accepted for publication May 24, 2006.